

Pthomegroup

	NAME	ORIGIN	INSERTION	ACTION	NERVE	
EYE EXPRESSIONS	Frontalis 1	galea aponeurotica	skin of eyebrows and root of nose	<ul style="list-style-type: none"> raises the eyebrows wrinkles the forehead horizontally 	Facial	
	Corrugator supercilii 2	arch of frontal bone above nasal bone	skin of eyebrow	<ul style="list-style-type: none"> draws eyebrows medially and inferiorly wrinkles the forehead vertically (frowning) 	Facial	
	Levator palpebrae superioris 3	tendinous band around optic foramen (near annular ring)	upper eyelid	<ul style="list-style-type: none"> raises eyelids 	Oculomotor	
	Orbicularis oculi 4	frontal and maxillary bones and ligaments around orbit	tissue of eyelid	<ul style="list-style-type: none"> blinking squinting draws eyebrows inferiorly 	Facial	

	NAME	ORIGIN	INSERTION	ACTION	NERVE	
EYEBALL MOVERS	Superior rectus 5	annular ring	superior eyeball	<ul style="list-style-type: none"> elevates the eye 	Oculomotor	
	Inferior rectus 6	annular ring	inferior eyeball	<ul style="list-style-type: none"> depresses the eye 	Oculomotor	
	Medial rectus 7	annular ring	medial eyeball	<ul style="list-style-type: none"> moves the eye medially 	Oculomotor	
	Lateral rectus 8	annular ring	lateral eyeball	<ul style="list-style-type: none"> moves the eye laterally 	Abducens	
	Superior oblique 9	annular ring	superior lateral eyeball via trochlea	<ul style="list-style-type: none"> depresses the eye & turns it laterally 	Trochlear	
	Inferior oblique 10	medial orbit surface	inferolateral eye surface	<ul style="list-style-type: none"> elevates the eye & turns it laterally 	Oculomotor	

Pthomegroup

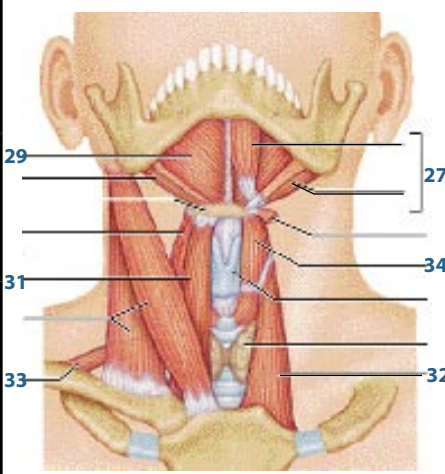
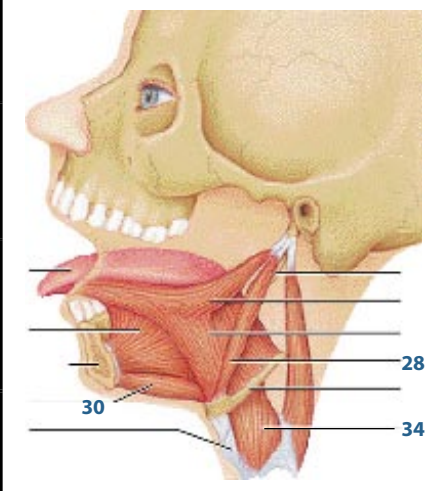
	NAME	ORIGIN	INSERTION	ACTION	NERVE	
MOUTH MOVERS	Levator labii superioris 11	zygomatic bone & infraorbital margin of maxilla	skin & muscle of upper lip	<ul style="list-style-type: none"> raises & furrows the upper lip 	Facial	
	Zygomaticus minor 12	zygomatic bone	skin & muscle @ corner of mouth	<ul style="list-style-type: none"> raises lateral corners of mouth (smiling) 	Facial	
	Zygomaticus major 13	zygomatic bone	skin & muscle @ corner of mouth	<ul style="list-style-type: none"> raises lateral corners of mouth (smiling) 	Facial	
	Risorius 14	lateral facia assoc. with masseter muscle	skin @ angle of mouth	<ul style="list-style-type: none"> draws corner of lip laterally tense of lips synergist of zygomaticus 	Facial	
	Buccinator 15	molar region of maxilla and mandible	orbicularis oris	<ul style="list-style-type: none"> draws corner of mouth laterally compresses cheek (sucking) holds food between teeth during chewing 	Facial	
	Depressor anguli oris 16	body of mandible below incisors	skin & muscle @ angle of mouth (below insertion of zygomaticus)	<ul style="list-style-type: none"> draws corner of mouth laterally & downward antagonist of zygomaticus 	Facial	
	Depressor labii inferioris 17	body and mandible lateral to its midline	skin & muscle of lower lip	<ul style="list-style-type: none"> draws lower lip inferiorly (pout) 	Facial	
	Orbicularis oris 18	arises directly from maxilla & mandible	encircles mouth; inserts into muscle & skin @ angles of mouth	<ul style="list-style-type: none"> closes lips purses and protrues lips kissing & whistling 	Facial	
	Platysma 19	fascia of chest (over pectoral muscle & deltoid)	lower margin of mandible, and skin & muscle @ corner of mouth	<ul style="list-style-type: none"> depresses mandible pulls lower lip back & down 	Facial	

Pthomegroup

	NAME	ORIGIN	INSERTION	ACTION	NERVE	
MANDIBLE MOVERS	Masseter 20	zygomatic arch and maxilla	angle & ramus of mandible	<ul style="list-style-type: none"> • prime mover of jaw closure • elevates mandible 	Trigeminal	
	Temporalis 21	temporal fossa	coronoid process of mandible	<ul style="list-style-type: none"> • closes jaw • elevates & retracts mandible • synergist of pterygoids • maintains position of mandible at rest 	Trigeminal	
	Medial pterygoid 22	medial surface of lateral pterygoid plate of sphenoid bone, maxilla & palatine bone	medial surface of mandible near its angle	<ul style="list-style-type: none"> • synergist of temporalis & masseter in elevation of the mandible • act with lateral pterygoid muscle to protrude mandible or to promote side-to-side movements (grinding) 	Trigeminal	
	Lateral pterygoid 23	greater wing & lateral pterygoid plate of sphenoid bone	condyle of mandible and capsule of temporomandibular joint	<ul style="list-style-type: none"> • protrudes mandible • provides forward sliding and side-to-side grinding movements of the lower teeth 	Trigeminal	

	NAME	ORIGIN	INSERTION	ACTION	NERVE	
TONGUE MOVERS	Genioglossus 24	internal surface of mandible near symphysis	inferior aspect of the tongue and body of hyoid bone	<ul style="list-style-type: none"> • primarily protrudes tongue • can depress or act in concert with other extrinsic muscles to retract tongue 	Hypoglossal	
	Styloglossus 25	styloid process of temporal bone	lateral inferior aspect of tongue	<ul style="list-style-type: none"> • retracts (& elevates) tongue 	Hypoglossal	
	Hyoglossus 26	body & greater horn of hyoid bone	inferolateral tongue	<ul style="list-style-type: none"> • depresses tongue & draws its sides downward 	Hypoglossal	

Pthomegroup

	NAME	ORIGIN	INSERTION	ACTION	NERVE	
SWALLOWING MUSCLES	Digastric 27	lower margin of mandible (anterior belly) & mastoid process of the temporal bone (posterior belly)	by a connective tissue loop to hyoid bone	<ul style="list-style-type: none"> acting in concert, elevate hyoid bone & steady it during swallowing & speech acting from behind, open mouth & depress mandible 	Mandibular branch of trigeminal (anterior belly) Facial (posterior belly)	
	Stylohyoid 28	styloid process of temporal bone	hyoid bone	<ul style="list-style-type: none"> elevates & retracts hyoid -> elongate floor of mouth during swallowing 	Facial	
	Mylohyoid 29	medial surface of mandible	hyoid bone & medial raphe	<ul style="list-style-type: none"> elevates hyoid bone & floor of mouth, enabling tongue to exert backward & upward pressure for swallowing 	Mandibular branch of trigeminal	
	Geniohyoid 30	inner surface of mandible	hyoid bone & medial raphe	<ul style="list-style-type: none"> pulls hyoid bone superiorly & anteriorly, shortening floor of mouth and widening pharynx for receiving food 	First cervical spinal nerve via hypoglossal nerve	
	Sternohyoid 31	manubrium & medial end of clavicle	lower margin of hyoid bone	<ul style="list-style-type: none"> depresses larynx & hyoid bone if mandible is fixed may also flex skull 	Cervical spinal nerves 1-3	
	Sternothyroid 32	posterior surface of manubrium	thyroid cartilage	<ul style="list-style-type: none"> pulls thyroid cartilage (plus larynx & hyoid) inferiorly 	Cervical spinal nerves 1-3	
	Omohyoid 33	superior surface of scapula	hyoid bone, lower border	<ul style="list-style-type: none"> depresses & retracts hyoid bone 	Cervical spinal nerves 1-3	
	Thyrohyoid 34	thyroid cartilage	hyoid bone	<ul style="list-style-type: none"> depresses hyoid bone elevates larynx if hyoid is fixed 	First cervical nerve via hypoglossal	

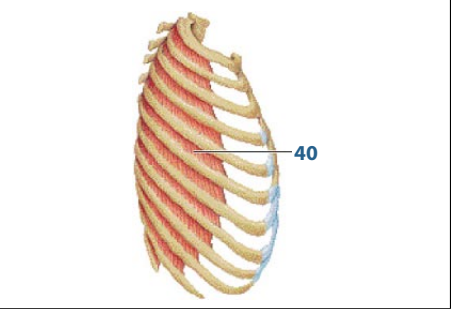
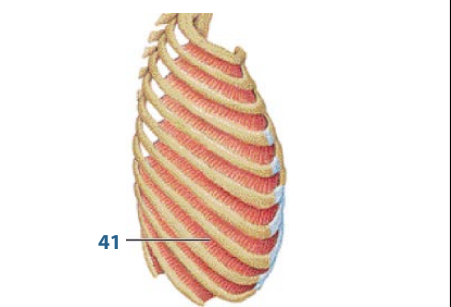
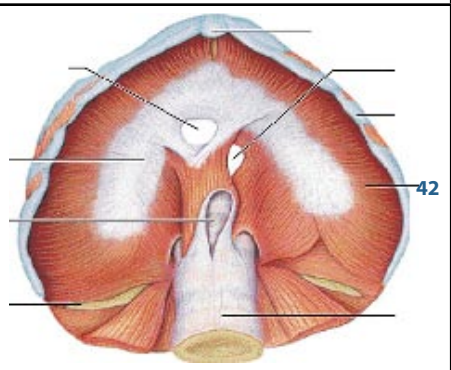
Pthomegroup

	NAME	ORIGIN	INSERTION	ACTION	NERVE	
WHOLE HEAD MOVERS	Sternocleidomastoid 35	manubrium of sternum & medial portion of clavicle	mastoid process of temporal bone & superior nuchal line of occipital bone	<ul style="list-style-type: none"> • prime mover of active head flexion (when act together) • rotates head toward opposite side (when act singularly) 	Accessory nerve	
	Splenius (capitis) 36	ligamentum nuchae, spinous process of vertebrae C7-T6	mastoid process of temporal bone & occipital bone (capitis)	<ul style="list-style-type: none"> • extend or hyperextend head when act together • rotate and bend head laterally toward same side when act on one side 	Cervical spinal nerves (dorsal rami)	
	Semispinalis capitis 37	transverse process of C7-T12	occipital bone (capitis)	<ul style="list-style-type: none"> • extends head and move it to opposite side • synergist with sternocleidomastoid of opposite side 	Spinal nerves (dorsal rami)	

Pthomegroup

	NAME	ORIGIN	INSERTION	ACTION	NERVE	
TORSO EXTENDERS	Erector spinae Iliocostalis 38-A	iliac crests (luborum) inferior 6 ribs (thoracis) ribs 3-6 (cervicis)	angle of ribs (luborum & thoracis) cervical vertebrae C6-C4 (cervicis)	<ul style="list-style-type: none"> • extend vertebral column, maintain posture • bend vertebral column to same side when act on one side 	Spinal nerves (dorsal rami)	
	Erector spinae Longissimus 38-B	transverse process of lumbar through cervical vertebrae	transverse process of thoracic or cervical vertebrae and to ribs superior to origin; mastoid process for capitis	<ul style="list-style-type: none"> • thoracis & cervicis act together to extend vertebral column • act on one side, bend it laterally • capitis extends heads and turns the face toward same side 	Spinal nerves (dorsal rami)	
	Erector spinae Spinalis 38-C	spines of upper lumbar & lower thoracic vertebrae	spines of upper thoracic & cervical vertebrae	<ul style="list-style-type: none"> • extends vertebral column 	Spinal nerves (dorsal rami)	
	Quadratus lumborum 39	iliac crest & lumbar fascia	transverse process of upper lumbar vertebrae & lower margin of 12th rib	<ul style="list-style-type: none"> • flexes vertebral column laterally when alone • when together extends lumbar spine & fixes 12th rib • maintains upright posture • assists in forced breathing 	T12 & upper lumbar spinal nerves (ventral rami)	

Pthomegroup

	NAME	ORIGIN	INSERTION	ACTION	NERVE	
BREATHING MUSCLES	External intercostals 40	inferior border of rib above	superior border of rib below	<ul style="list-style-type: none"> • elevate rib cage, aids in inspiration • synergist of diaphragm 	Intercostal	
	Internal intercostals 41	superior border of rib below	inferior border (costal groove) of rib above	<ul style="list-style-type: none"> • depress rib cage, aid in forced expiration • antagonist of external intercostals 	Intercostal	
	Diaphragm 42	inferior, internal surface of rib cage & sternum, costal cartilages of last six ribs & lumbar vertebrae	central tendon	<ul style="list-style-type: none"> • prime mover of inspiration, flattens on contraction 	Phrenic	

Pthomegroup

	NAME	ORIGIN	INSERTION	ACTION	NERVE	
ABDOMINAL MUSCLES	Rectus Abdominis 43	pubic crest & symphysis	xyphoid process & costal cartilages of ribs 5-7	<ul style="list-style-type: none"> flex & rotate lumbar region of vertebral column fix & depress ribs stabilize pelvis during walking increase intra-abdominal pressure 	Intercostals	
	External oblique 44	outer surface of lower 8 ribs	linea alba via aponeurosis	<ul style="list-style-type: none"> when together, synergist to rectus abdominis, flex vertebral column & compress abdominal wall when alone, synergist to muscles of back, rotate & lateral flexion of trunk 	Intercostals	
	Internal oblique 45	lumbar fascia, iliac crest, & inguinal ligament	linea alba, pubic crest, last 3 or 4 ribs, & costal margin	<ul style="list-style-type: none"> same as external oblique 	Intercostals	
	Transverse abdominis 46	inguinal ligament, lumbar fascia, cartilages of last 6 ribs, iliac crest	linea alba, pubic crest	<ul style="list-style-type: none"> compresses abdominal contents 	Intercostals	

	NAME	ORIGIN	INSERTION	ACTION	NERVE	
PELVIC FLOOR MUSCLES	Levator ani 47	inside pelvis from pubis to ischial spine	inner surface of coccyx	<ul style="list-style-type: none"> supports & maintains pelvic viscera resists downward thrusts forms sphincters at ano-rectal junction & vagina lifts anal canal during defecation 	S4 & inferior rectal	
	Coccygeus 48	spine of ischium	sacrum & coccyx	<ul style="list-style-type: none"> supports pelvic viscera supports coccyx & pulls it forward 	S4 & S5	

Pthomegroup

	NAME	ORIGIN	INSERTION	ACTION	NERVE	
SHOULDER MOVERS	Pectoralis minor 49	anterior surface of ribs 3-5 (or 2-4)	coracoid process of scapula	<ul style="list-style-type: none"> draws scapula forward & downward (ribs fixed) draws rib cage superiorly (scapula fixed) 	Both pectoral nerves	
	Subclavius 50	costal cartilage of rib 1	groove on inferior surface of clavicle	<ul style="list-style-type: none"> stabilizes & depresses pectoral girdle 	Nerve to subclavius	
	Serratus anterior (boxer's muscle) 51	by series of muscle slips from ribs 1-9	anterior surface of vertebral border of scapula	<ul style="list-style-type: none"> agonist to protract & hold scapula against rib cage rotates scapula (inferior angle laterally & upward) abduct & raise arm & horizontal arm movements 	Long thoracic nerve	
	Trapezius 52	occipital bone, ligamentum nuchae, spines of C7 - T12	spine & acromion of scapula, lateral 3rd of clavicle	<ul style="list-style-type: none"> stabilizes, raises, retracts & rotates scapula adducts & retracts scapula (middle) elevates scapula or synergist to head extension (superior) depresses scapula & shoulder (inferior) 	Accessory nerve	
	Levator scapulae 53	transverse processes of C1-C4	medial border of scapula, superior to spine	<ul style="list-style-type: none"> elevates & adducts scapula (synergist to trapezius) tilts glenoid cavity down, flexes neck to same side (fixed scapula) 	Cervical spinal nerves & dorsal scapular nerve	
	Rhomboid minor 54	spinous processes of C7 & T1	medial border of scapula	<ul style="list-style-type: none"> retract scapula (squaring shoulders), synergist with middle fibers of Trapezius 	Dorsal scapular nerve	
	Rhomboid major 55	spinous processes of T2-T5	medial border of scapula	<ul style="list-style-type: none"> rotate glenoid cavity downward (lowering arm against resistance) stabilize scapula 		

Pthomegroup

	NAME	ORIGIN	INSERTION	ACTION	NERVE	
ARM MOVERS	Pectoralis major 56	sternal end of clavicle, sternum, cartilage of ribs 1-6, & aponeurosis of external oblique muscle	by a short tendon into intertubercular groove of humerus	<ul style="list-style-type: none"> • agonist of arm flexion • rotates arm medially • adducts arm against resistance • pulls rib cage upward with scapula fixed 	Lateral & medial pectoral nerves	
	Latissimus dorsi 57	via lumbodorsal fascia into spines of T7-L5, lower 4 ribs & iliac crest	floor of intertubercular groove of humerus	<ul style="list-style-type: none"> • agonist of arm extension • powerful arm adductor • medially rotates arm & shoulder • depresses scapula • pulls body upward & forward with arms fixed overhead 	Thoracodorsal	
	Deltoid 58	lateral 3rd of clavicle, acromion & spine of scapula	deltoid tuberosity of humerus	<ul style="list-style-type: none"> • agonist of arm abduction with all fibers, antagonist of pectoralis major & latissimus dorsi • flexes & medially rotates humerus with anterior fibers, synergist of pectoralis major • extends & laterally rotates arms with posterior fibers 	Axillary nerve	
	Supraspinatus 59	supraspinous fossa of scapula	superior part of greater tubercle of humerus	<ul style="list-style-type: none"> • stabilizes shoulder joint • helps prevent downward dislocation of humerus 	Suprascapular nerve	
	Infraspinatus 60	infraspinous fossa of scapula	greater tubercle of humerus, posterior to supraspinatus	<ul style="list-style-type: none"> • helps to hold head of humerus in glenoid cavity • stabilizes the shoulder joint • rotates humerus laterally 	Suprascapular nerve	
	Subscapularis 61	subscapular fossa of scapula	lesser tubercle of humerus	<ul style="list-style-type: none"> • chief medial rotator of humerus, assisted by pectoralis major • helps to hold head of humerus in glenoid cavity, stabilizes shoulder 	Subcapular nerve	
	Teres minor 62	lateral border of dorsal scapular surface	greater tubercle of humerus, inferior to infraspinatus	same as infraspinatus	Axillary nerve	
	Teres major 63	posterior surface of scapula @ inferior angle	intertubercular groove of humerus, tendon fused with tendon of latissimus dorsi	<ul style="list-style-type: none"> • posteromedially extends, medially rotates, & adducts arm • synergist of latissimus dorsi 	Lower scapular nerve	
	Coracobrachialis 64	coracoid process of scapula	medial surface of humerus shaft	<ul style="list-style-type: none"> • flexion & adduction of humerus • synergist of pectoralis major 	Musculocutaneous nerve	

Pthomegroup

	NAME	ORIGIN	INSERTION	ACTION	NERVE	
FOREARM MOVERS	Biceps brachii 65	long head (65-1): tubercle above glenoid cavity and lip of glenoid cavity of scapula short head: (65-2): coracoid process of scapula	by common tendon to radial tuberosity	<ul style="list-style-type: none"> flexes elbow joint & supinates forearm (usually at the same time) weak flexor of arm @ shoulder 	Musculocutaneous nerve	
	Brachialis 66	front of distal humerus	coronoid process of ulna	<ul style="list-style-type: none"> major forearm flexor, synergist with biceps brachii 	Musculocutaneous nerve	
	Brachioradialis 67	lateral supracondylar ridge @ distal end of humerus	base of styloid process of radius	<ul style="list-style-type: none"> synergist in forearm flexion, best when forearm is partially flexed stabilizes the elbow during rapid flexion & extension 	Radial nerve	
	Triceps brachii 68	lateral head (68-1): posterior shaft of humerus long head (68-2): infraglenoid tubercle of scapula medial head (68-3): posterior humeral shaft distal to radial groove	by common tendon into olecranon process of ulna	<ul style="list-style-type: none"> agonist of forearm extension (medial head) antagonist of forearm flexors stabilizes shoulder joint & assist in arm adduction (long head tendon) 	Radial nerve	
	Anconeus 69	lateral epicondyle of humerus	lateral aspect of olecranon process	<ul style="list-style-type: none"> abducts ulna during forearm pronation synergist of triceps brachii in elbow extension 	Radial nerve	
FOREARM ROTATORS	Pronator teres 70	medial epicondyle of humerus, coronoid process of ulna	by common tendon into lateral radius, midshaft	<ul style="list-style-type: none"> pronates forearm weak flexor of elbow 	Median nerve	
	Supinator 71	lateral epicondyle of humerus, radial collateral & annular ligaments, supinator fossa & crest of ulna	lateral, anterior & posterior surfaces of proximal 1/3 of radius	<ul style="list-style-type: none"> forcibly supinates forearm with biceps brachii weakly supinates forearm working along antagonist of Pronator teres 	Posterior interosseous nerve	

Pthomegroup

	NAME	ORIGIN	INSERTION	ACTION	NERVE	
WRIST FLEXORS	Flexor carpi radialis 72	medial epicondyle of humerus	base of 2nd & 3rd metacarpals (anterior)	<ul style="list-style-type: none"> powerful flexor of wrist abducts the hand weak synergist of elbow flexion 	Median nerve	
	Palmaris longus 73	medial epicondyle of humerus	palmar aponeurosis, skin & fascia of palm	<ul style="list-style-type: none"> weak wrist flexor weak synergist of elbow flexion tenses skin of palm during hand movements 	Median nerve	
	Flexor carpi ulnaris 74	medial epicondyle of humerus, olecranon process & posterior surface of ulna	pisiform & hamate bones & base of 5th metacarpal (anterior)	<ul style="list-style-type: none"> powerful flexor of wrists adducts hand with extensor carpi ulnaris stabilized wrist during finger extension 	Ulnar nerve	
WRIST EXTENSORS	Extensor carpi radialis longus 75	lateral supracondylar ridge of humerus	base of 2nd metacarpal (posterior)	<ul style="list-style-type: none"> extends wrist with extensor carpi ulnaris abducts wrist with flexor carpi radialis 	Radial nerve	
	Extensor carpi ulnaris 76	lateral epicondyle of humerus & posterior border of ulna	base of 5th metacarpal (posterior)	<ul style="list-style-type: none"> extends & adducts wrist 	Deep branch of radial nerve	
FINGER MOVERS	Flexor digitorum superficialis 77	medial epicondyle of humerus, coronoid process of ulna, shaft of radius	by four tendons into middle phalanges of fingers 2-5	<ul style="list-style-type: none"> flexes wrist & middle phalanges of fingers 2-5 	Median nerve	
	Extensor digitorum 78	lateral epicondyle of humerus	by four tendons into extensor expansions & distal phalanges of fingers 2-5	<ul style="list-style-type: none"> prime mover of finger extension extends wrist can abduct (flare) fingers 	Posterior interosseous nerve, a branch of radial nerve	
	Extensor digiti minimi 79	lateral epicondyle of humerus	extensor expansion of 5th digit	<ul style="list-style-type: none"> extends 5th digit 	Posterior interosseous nerve, deep branch of radial nerve	
	Extensor pollicis longus 80	posterior surface of middle 3rd of ulna	base of distal phalanx of thumb	<ul style="list-style-type: none"> extends thumb 	Posterior interosseous nerve	
	Abductor pollicis longus 81	posterior surface of radius & ulna	base of 1st metacarpal & trapezium	<ul style="list-style-type: none"> abducts & extends thumb 	Posterior interosseous nerve	

Pthomegroup

	NAME	ORIGIN	INSERTION	ACTION	NERVE	
THIGH MOVERS	Sartorius 82	anterior superior iliac spine	medial aspect of proximal tibia	<ul style="list-style-type: none"> flexes, abducts & laterally rotates the thigh flexes knee (weak) 	Femoral nerve	
	Iliopsoas Iliacus 83	iliac fossa & crest, lateral sacrum	lesser trochanter of femur	<ul style="list-style-type: none"> prime mover of thigh flexion lateral flexion of vertebral column (psoas) 	Femoral nerve	
	Iliopsoas Psoas major 84	transverse processes of L1-L5, bodies & discs of T12-L5	lesser trochanter of femur		Ventral nerve	
	Pectineus 85	pectineal line of pubis	inferior from lesser trochanter to linea aspera	<ul style="list-style-type: none"> adducts, flexes & medially rotates thigh 	Femoral & obturator nerve	
	Gracilis 86	inferior ramus & body of pubis, ischial ramus	medial surface of tibial shaft just inferior to medial condyle	<ul style="list-style-type: none"> adducts thigh flexes & medially rotates leg (when walking) 	Obturator nerve	
	Adductor magnus 87	ischial & pubic rami, ischial tuberosity	linea aspera & adductor tubercle of femur	<ul style="list-style-type: none"> adducts & medially rotates thigh (anterior part) synergist of hamstring in thigh extension (posterior part) 	Obturator nerve	
	Adductor longus 88	pubic near pubic symphysis	linea aspera	<ul style="list-style-type: none"> adducts, flexes & medially rotates thigh 	Anterior division of obturator nerve	
	Tensor fasciae latae 89	anterior iliac crest & anterior superior iliac spine	iliotibial tract	<ul style="list-style-type: none"> flexes & abducts thigh (synergist of iliopsoas & gluteus muscles) rotates thigh medially steadies the trunk by pulling iliotibial tract taut (locking the knee) 	Superior gluteal nerve	
	Gluteus maximus 90	dorsal ilium, sacrum & coccyx	gluteal tuberosity of femur, iliotibial tract	<ul style="list-style-type: none"> major extensor of thigh laterally rotates & abducts thigh inactive during standing 	Inferior gluteal nerve	
	Gluteus medius 91	lateral surface of ilium between anterior & posterior gluteal lines	via short tendon into lateral aspect of greater trochanter	<ul style="list-style-type: none"> abducts thigh anterior part rotates hip medially posterior part rotates hip laterally 	Superior gluteal nerve	
Gluteus minimus 92	dorsal ilium between anterior & inferior gluteal lines	superior border of greater trochanter of femur	<ul style="list-style-type: none"> abducts & medially rotates thigh 	Superior gluteal nerve		

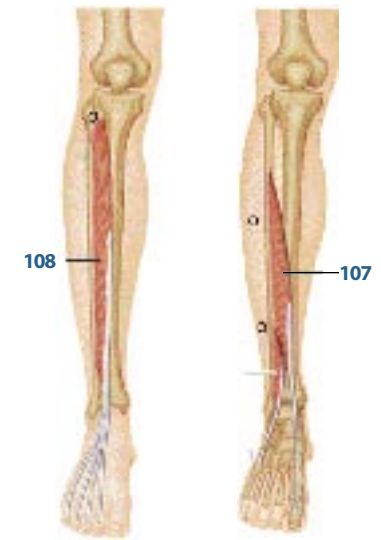
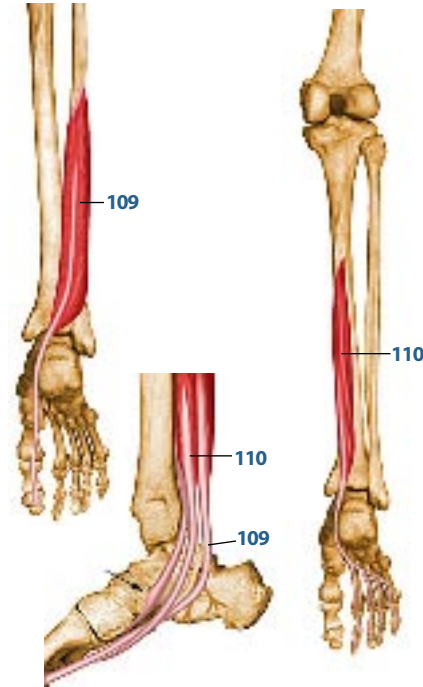
Pthomegroup

	NAME	ORIGIN	INSERTION	ACTION	NERVE	
HAMSTRINGS	Biceps femoris 93	long head (a): ischial tuberosity short head (b): linea aspera & distal femur	by common tendon into head of fibula & lateral condyle of tibia	<ul style="list-style-type: none"> extends thigh & flexes knee laterally rotates leg when knee is flexed 	Sciatic nerve	
	Semitendinosus 94	ischial tuberosity	medial aspect of upper tibial shaft	<ul style="list-style-type: none"> extends thigh & flexes knee medially rotates leg with semimembranosus 	Sciatic nerve	
	Semimembranosus 95	ischial tuberosity	medial condyle of tibia	<ul style="list-style-type: none"> extends thigh & flexes knee medially rotates leg 	Sciatic nerve	
	Popliteus 96	lateral condyle of femur	proximal tibia (posterior surface)	<ul style="list-style-type: none"> unlocks knee by flexes & rotates leg medially rotates thigh laterally with tibia fixed 	Tibial nerve	
QUADRICEPS	Rectus femoris 97	anterior inferior iliac spine & superior margin of acetabulum	patella & tibial tuberosity via patella ligament	<ul style="list-style-type: none"> extends knee flexes thigh @ hip 	Femoral nerve	
	Vastus lateralis 98	greater trochanter, intertrochanteric line, linea aspera		<ul style="list-style-type: none"> extends & stabilizes knee 	Femoral nerve	
	Vastus medialis 99	linea aspera, intertrochanteric line		<ul style="list-style-type: none"> extends knee stabilizes patella (inferior fibers) 	Femoral nerve	
	Vastus intermedius 100	anterior & lateral surfaces of proximal femur		<ul style="list-style-type: none"> extends knee 	Femoral nerve	

Pthomegroup

	NAME	ORIGIN	INSERTION	ACTION	NERVE	
FOOT MOVERS	Tibialis anterior 101	lateral condyle & upper 2/3 of tibial shaft, interosseous membrane	by tendon into inferior surface of medial cuneiform & 1st metatarsal	<ul style="list-style-type: none"> • prime mover of dorsiflexion • inverts foot • assist in supporting medial longitudinal arch 	Deep fibular nerve	
	Fibularis longus 102	head & upper portion of lateral fibula	by long tendon underfoot into 1st metatarsal & medial cuneiform	<ul style="list-style-type: none"> • plantar flexes & everts foot • may help keep foot flat on ground 	Superficial fibular nerve	
	Fibularis brevis 103	distal fibula shaft	by tendon behind lateral malleolus into base of 5th metatarsal	<ul style="list-style-type: none"> • plantar flexes & everts foot 	Superficial fibular nerve	
	Gastrocnemius 104	by two heads from medial & lateral condyles of femur	posterior calcaneus via calcaneal tendon (Achilles)	<ul style="list-style-type: none"> • plantar flexes foot when knee is extended • flexes knee when foot is dorsiflexed 	Tibial nerve	
	Soleus 105	superior tibia, fibula & interosseous membrane		<ul style="list-style-type: none"> • plantar flexes foot • important locomoter & postural muscle 	Tibial nerve	
	Plantaris 106	posterior femur above lateral condyle	via a long, thin tendon into calcaneus or calcaneal tendon	<ul style="list-style-type: none"> • assists in knee flexion • plantar flexion of foot 	Tibial nerve	

Pthomegroup

	NAME	ORIGIN	INSERTION	ACTION	NERVE	
TOE MOVERS	Extensor hallucis longus 107	anteromedial fibula shaft & interosseous membrane	distal phalanx of big toe	<ul style="list-style-type: none"> • extends big toe • dorsiflexes foot 	Deep fibular nerve	
	Extensor digitorum longus 108	lateral condyle of tibia, proximal 3/4 of fibula, interosseous membrane	middle & distal phalanges of toes 2-5 via extensor expansion	<ul style="list-style-type: none"> • prime mover of toe extension (mainly @ metatarsal joints) • dorsiflexes foot (with tibialis anterior & extensor hallucis longus) 	Deep fibular nerve	
	Flexor hallucis longus 109	mid-shaft of fibula, interosseous membrane	tendon runs underfoot to distal phalanx of big toe	<ul style="list-style-type: none"> • plantar flexes & inverts foot • flexes big toe (push-off muscle when walking) 	Tibial nerve	
	Flexor digitorum longus 110	posterior tibia	tendon runs behind medial malleolus & insert into distal phalanx of toes 2-5	<ul style="list-style-type: none"> • plantar flexes & inverts foot • flexes toes • helps foot "grip" ground 	Tibial nerve	