

CHAPTER CONTENTS

Possible causes of pain and/or limitation of movement 129

Subjective examination 130

- Body chart 130
- Behaviour of symptoms 131
- Special questions 133
- History of the present condition (HPC) 133
- Past medical history (PMH) 134
- Social and family history 134
- Plan of the physical examination 134

Physical examination 134

- Observation 134
- Joint tests 135
- Muscle tests 139
- Neurological tests 141
- Special tests 141
- Functional ability 142
- Palpation 142
- Passive accessory intervertebral movements (PAIVMs) 143

Completion of the examination 146

5

Examination of the upper cervical spine

POSSIBLE CAUSES OF PAIN AND/OR LIMITATION OF MOVEMENT

The upper cervical spine is defined here as the occiput and upper three cervical vertebrae (C1–3) with their surrounding soft tissues.

- **Trauma**
 - Whiplash
 - Fracture of vertebral body, spinous or transverse process
 - Ligamentous sprain
 - Muscular strain
- **Degenerative conditions**
 - Spondylosis – degeneration of C2–C3 intervertebral disc
 - Arthrosis – degeneration of zygapophyseal joints
- **Inflammatory conditions**
 - Rheumatoid arthritis
 - Ankylosing spondylitis
- **Neoplasm**
- **Infection**
- **Headache due to (Headache Classification Committee of the International Headache Society 1988)**
 - Migraine
 - Tension-type headache

- Cluster headache
- Miscellaneous headaches unassociated with structural lesion, e.g. cold stimulus headache, cough or exertional headache
- Headache associated with head trauma
- Headache associated with vascular disorders, e.g. transient ischaemic attack, intracranial haematoma, subarachnoid headache, arterial hypertension, carotid or vertebral artery pain
- Headache associated with non-vascular disorders, e.g. high or low cerebrospinal fluid pressure, intracranial infection or neoplasm
- Headache associated with substances or their withdrawal, e.g. monosodium glutamate, alcohol, analgesic abuse, caffeine, narcotics
- Headache associated with non-cephalic infection, e.g. bacterial or viral infection
- Headache associated with metabolic disorder, e.g. hypoxia, hypercapnia, sleep apnoea, hypoglycaemia
- Headache or facial pain associated with disorder of cranium, neck, eyes, ears, nose, sinuses, teeth, mouth or other facial or cranial structures, e.g. cervical spine, glaucoma of the eyes, acute sinus headache, temporomandibular joint disease
- Cranial neuralgias, nerve trunk pain and deafferentation pain, e.g. diabetic neuritis, neck–tongue syndrome, herpes zoster, trigeminal neuralgia, occipital neuralgia
- Headache not classifiable

Further details of the questions asked during the subjective examination and the tests carried out in the physical examination can be found in Chapters 2 and 3 respectively.

The order of the subjective questioning and the physical tests described below can be altered as appropriate for the patient being examined.

SUBJECTIVE EXAMINATION

Body chart

The following information concerning the area and type of current symptoms should be recorded on a body chart (Fig. 2.4).

Area of current symptoms

Be exact when mapping out the area of the symptoms. Typically, patients with upper cervical spine disorders have neck pain high up around the occiput and pain over the head and/or face. Ascertain which is the worst symptom and record where the patient feels the symptoms are coming from.

Areas relevant to the region being examined

Clear all other areas relevant to the region being examined, especially between areas of pain, paraesthesia, stiffness or weakness. Mark these unaffected areas with ticks (✓) on the body chart. Check for symptoms in the lower cervical spine, thoracic spine, head and temporomandibular joint and if the patient has ever experienced any dizziness. This is relevant for symptoms emanating from the cervical spine where vertebrobasilar insufficiency (VBI) may be provoked. If dizziness is a feature described by the patient, the clinician determines what factors aggravate and what factors ease the symptoms, the duration and severity of the dizziness and its relationship with other symptoms such as disturbance in vision, diplopia, nausea, ataxia, 'drop attacks', impairment of trigeminal sensation, sympathoplegia, dysarthria, hemianaesthesia and hemiplegia (Bogduk 1994). In addition, the vertebral artery tests must be carried out in the physical examination (see below).

Quality of pain

Establish the quality of the pain. Headaches of cervical origin are often described as throbbing or as a pressure sensation. If the patient suffers from headaches, find out if there is any associated blurred vision, loss of balance, tinnitus, audi-

tory disturbance, swelling and stiffness of the fingers, tendinitis and capsulitis, which could be due to irritation of the sympathetic plexus surrounding the vertebral artery or to irritation of the spinal nerve (Jackson 1966). Patients who have suffered a hyperextension injury to the cervical spine may complain of a sore throat, difficulty in swallowing and a feeling of something stuck in their throat resulting from an associated injury to the oesophagus (Dahlberg et al 1997).

Intensity of pain

The intensity (I) of a headache can be categorized into five grades (Edeling 1988):

- Grade I1 – mild pain
- Grade I2 – more than mild pain but tolerable
- Grade I3 – moderately severe pain
- Grade I4 – severe pain
- Grade I5 – intolerable, perhaps suicidal pain.

The intensity of pain can also be measured using, for example, a visual analogue scale (VAS) as shown in the examination chart at the end of this chapter (Fig. 5.19). A pain diary may be useful for patients with chronic neck pain or headaches to determine the pain patterns and triggering factors which may be unusual or complex.

Depth of pain

Discover the patient's interpretation of the depth of the pain.

Abnormal sensation

Check for any altered sensation locally over the cervical spine and head, as well as the face and upper limbs. Common abnormalities are paraesthesia and numbness.

Constant or intermittent symptoms

Ascertain the frequency of the symptoms, and whether they are constant or intermittent. If symptoms are constant, check whether there is variation in the intensity of the symptoms, as constant unremitting pain may be indicative of neoplastic disease.

The frequency or periodicity (P) of headaches can be categorized into five grades (Edeling 1988):

- Grade P1 – pain on one day per month or less
- Grade P2 – pain on two or more days per month
- Grade P3 – pain on one or more days a week
- Grade P4 – daily but intermittent pain
- Grade P5 – continuous pain.

Relationship of symptoms

Determine the relationship between the symptomatic areas – do they come together or separately? For example, the patient could have a headache without the cervical pain, or they may always be present together.

Behaviour of symptoms

Aggravating factors

For each symptomatic area, discover what movements and/or positions aggravate the patient's symptoms, i.e. what brings them on (or makes them worse), how long it takes to aggravate them and what happens to other symptom(s) when one symptom is produced (or is made worse). These questions help to confirm the relationship between the symptoms.

The clinician also asks the patient about theoretically known aggravating factors for structures that could be a source of the symptoms. Common aggravating factors for the upper cervical spine are sustained cervical postures and movements. Headaches can be brought on with eye strain, noise, excessive eating, drinking, smoking, stress or inadequate ventilation. Aggravating factors for other joints, which may need to be queried if any of these joints is suspected to be a source of the symptoms, are shown in Table 2.3.

Easing factors

For each symptomatic area, the clinician asks what movements and/or positions ease the patient's symptoms, how long it takes to ease them and what happens to other symptom(s) when one symptom is relieved. These questions

help to confirm the relationship between the symptoms.

The clinician asks the patient about theoretically known easing factors for structures that could be a source of the symptoms. For example, symptoms from the upper cervical spine may be eased by supporting the head or neck. The clinician should analyse the position or movement that eases the symptoms in order to help determine the structure at fault.

The ease with which headaches respond (R) to analgesics can be categorized into five grades (Edeling 1988):

- Grade R1 – pain abates readily with small doses of simple analgesics
- Grade R2 – pain is lessened but does not go away with simple analgesics
- Grade R3 – pain is totally relieved by compound analgesic
- Grade R4 – pain is lessened but does not go away with a large dose of compound analgesic
- Grade R5 – no dose of any analgesic has any effect at all on the pain.

Severity and irritability of symptoms

Severity and irritability are used to identify patients who will not be able to tolerate a full physical examination. If the patient is able to sustain a position that reproduces the symptoms then the condition is considered non-severe and overpressures can be applied in the physical examination. If the patient is unable to sustain the position, the condition is considered severe and no overpressures should be attempted.

If symptoms ease immediately following provocation then the condition is considered to be non-irritable and all movements can be tested in the physical examination. If the symptoms take a few minutes to ease, the symptoms are irritable and only a few movements should be attempted to avoid exacerbating the patient's symptoms.

Twenty-four hour behaviour of symptoms

The clinician determines the 24-hour behaviour of the symptoms by asking questions about night, morning and evening symptoms.

Night symptoms. The following questions should be asked:

- Do you have any difficulty getting to sleep?
- What position is most comfortable/uncomfortable?
- What is your normal sleeping position?
- What is your present sleeping position?
- Do your symptom(s) wake you at night? If so,
 - Which symptom(s)?
 - How many times in the past week?
 - How many times in a night?
 - How long does it take to get back to sleep?
- How many and what type of pillows are used? Is the mattress firm or soft?

Morning and evening symptoms. The clinician determines the pattern of the symptoms first thing in the morning, through the day and at the end of the day. Stiffness in the morning for the first few minutes might suggest cervical spondylosis; stiffness and pain for a few hours is suggestive of an inflammatory process such as rheumatoid arthritis.

Function

The clinician ascertains how the symptoms vary according to various daily activities, such as:

- Static and active postures, e.g. sitting, standing, lying, washing, ironing, dusting, driving, reading, writing, etc. Establish whether the patient is left- or right-handed.
- Work, sport and social activities that may be relevant to the cervical spine.

Detailed information about each of the above activities is useful to help determine the structure at fault and to identify clearly the functional restrictions. This information can be used to determine the aims of treatment and any advice that may be required. The most important functional restrictions are highlighted with asterisks (*) and reassessed at subsequent treatment sessions to evaluate treatment intervention.

Stage of the condition

In order to determine the stage of the condition, the clinician asks whether the symptoms are

getting better, getting worse or remaining unchanged.

Special questions

Special questions must always be asked as they may identify certain precautions or absolute contraindications to further examination and treatment techniques (Table 2.4). As mentioned in Chapter 2, the clinician must differentiate between conditions that are suitable for conservative management and systemic, neoplastic and other non-neuromusculoskeletal conditions, which require referral to a medical practitioner. The reader is referred to Appendix 2 of Chapter 2 for details of various serious pathological processes that can mimic neuromusculoskeletal conditions (Grieve 1994).

The following information should be obtained routinely for all patients:

General health. The clinician ascertains the state of the patient's general health – find out if the patient suffers any malaise, fatigue, fever, epilepsy, diabetes, nausea or vomiting, stress, anxiety or depression.

Weight loss. Has the patient noticed any recent unexplained weight loss?

Rheumatoid arthritis. Has the patient (or a member of his/her family) been diagnosed as having rheumatoid arthritis?

Drug therapy. Find out what drugs are being taken by the patient. Has the patient ever been prescribed long-term (6 months or more) medication or steroid therapy? Has the patient been taking anticoagulants recently?

X-rays and medical imaging. Has the patient been X-rayed or had any other medical tests recently? Routine spinal X-rays are no longer considered necessary prior to conservative treatment as they only identify the normal age-related degenerative changes, which do not necessarily correlate with the patient's symptoms (Clinical Standards Advisory Report 1994). The medical tests may include blood tests, magnetic resonance imaging, myelography, discography or a bone scan.

Neurological symptoms. Has the patient experienced symptoms of spinal cord compression, which are bilateral tingling in the hands or feet and/or disturbance of gait?

Box 5.1 Risk factors for symptoms related to vertebrobasilar insufficiency (Barker et al 2000)

- Drop attacks, blackouts, loss of consciousness
- Nausea, vomiting and general unwell feelings
- Dizziness or vertigo, particularly if associated with head positioning
- Disturbances of vision (e.g. decreased, blurred, diplopia)
- Unsteadiness of gait (ataxia) and general feeling of weakness
- Tingling or numbness (especially dysaesthesia, i.e. tingling around the lips, hemianaesthesia or any alteration in facial sensation)
- Difficulty in speaking (dysarthria) or swallowing
- Hearing disturbance (e.g. tinnitus, deafness)
- Headache
- Past history of trauma
- Cardiac disease, vascular disease, altered blood pressure, previous cerebrovascular accident or transient ischaemic attacks
- Blood clotting disorders
- Anticoagulant therapy
- Oral contraceptives
- Long-term use of steroids
- A history of smoking
- Immediately post partum

Dizziness. This has been explored previously in the body chart section. Risk factors for symptoms of vertebrobasilar insufficiency are given in Box 5.1.

History of the present condition (HPC)

For each symptomatic area the clinician should discover how long the symptom has been present, whether there was a sudden or slow onset and whether there was a known cause that provoked the onset of the symptom. If the patient complains of headaches, the clinician should find out whether there have been any factors that precipitated the onset, such as trauma, stress, surgery or occupation. If the onset was slow, the clinician should find out if there has been any change in the patient's life-style, e.g. a new job or hobby or a change in sporting activity, that has increased the mechanical stress on the cervical spine or increased the patient's stress levels. To confirm the relationship between the symptoms, the clinician asks what happened to other symptoms when each symptom began.

Past medical history (PMH)

The following information should be obtained from the patient and/or the medical notes:

- The details of any relevant medical history involving the cervical spine and related areas.
- The history of any previous attacks: how many episodes, when were they, what was the cause, what was the duration of each episode and did the patient fully recover between episodes? If there have been no previous attacks, has the patient had any episodes of stiffness in the cervical spine, thoracic spine or any other relevant region? Check for a history of trauma or recurrent minor trauma.
- Ascertain the results of any past treatment for the same or similar problem. Past treatment records may be obtained for further information.

Social and family history

Social and family history that is relevant to the onset and progression of the patient's problem should be recorded. Examples of relevant information might include the age of the patient, employment, the home situation, any dependants and details of any leisure activities. Factors from this information may indicate direct and/or indirect mechanical influences on the cervical spine. In order to treat the patient appropriately, it is important that the condition is managed within the context of the patient's social and work environment.

Plan of the physical examination

When all this information has been collected, the subjective examination is complete. It is useful at this stage to highlight with asterisks (*), for ease of reference, important findings and particularly one or more functional restrictions. These can then be re-examined at subsequent treatment sessions to evaluate treatment intervention.

In order to plan the physical examination, the following hypotheses need to be developed from the subjective examination:

- Structures that must be examined as a possible cause of the symptoms, e.g.

temporomandibular joint, upper cervical spine, cervical spine, thoracic spine, soft tissues, muscles and neural tissues. Often it is not possible to examine fully at the first attendance and so examination of the structures must be prioritized over subsequent treatment sessions.

- Other factors that need to be examined, e.g. working and everyday postures, vertebral artery, muscle weakness.
- An assessment of the patient's condition in terms of severity, irritability and nature (SIN):
 - Severity of the condition: if severe, no overpressures are applied
 - Irritability of the condition: if irritable, fewer movements are carried out
 - Nature of the condition: the physical examination may require caution in certain conditions such as vertebrobasilar insufficiency, neurological involvement, recent fracture, trauma, steroid therapy or rheumatoid arthritis; there may also be certain contraindications to further examination and treatment, e.g. symptoms of cord compression.

A physical examination planning form can be useful for clinicians to help guide them through the clinical reasoning process (Figs 2.11 & 2.12).

PHYSICAL EXAMINATION

Throughout the physical examination, the clinician must aim to find physical tests that reproduce each of the patient's symptoms. Each of these positive tests is highlighted by an asterisk (*) and used to determine the value of treatment intervention within and between treatment sessions. The order and detail of the physical tests described below need to be appropriate to the patient being examined. Some tests will be irrelevant, others will only need to be carried out briefly, while others will need to be fully investigated.

Observation

Informal observation

The clinician should observe the patient in dynamic and static situations; the quality of

movement is noted, as are the postural characteristics and facial expression. Informal observation will have begun from the moment the clinician begins the subjective examination and will continue to the end of the physical examination.

Formal observation

Observation of posture. The clinician examines spinal posture in sitting and standing, noting the posture of head and neck, thoracic spine and upper limbs. The clinician passively corrects any asymmetry to determine its relevance to the patient's problem.

A specific abnormal posture relevant to the upper cervical spine is the shoulder crossed syndrome (Janda 1994), which was described in Chapter 3. Patients who experience headaches may have a forward head posture (Watson 1994).

It should be noted that pure postural dysfunction rarely influences one region of the body in isolation and it may be necessary to observe the patient more fully for a full postural examination.

Observation of muscle form. The clinician observes the muscle bulk and muscle tone of the patient, comparing left and right sides. It must be remembered that handedness and level and frequency of physical activity may well produce differences in muscle bulk between sides. Some muscles are thought to shorten under stress, while other muscles weaken, producing muscle imbalance (Table 3.2). Patterns of muscle imbalance are thought to be the cause of the shoulder crossed syndrome mentioned above, as well as other abnormal postures outlined in Table 6.1.

Observation of soft tissues. The clinician observes the colour of the patient's skin and notes any swelling over the cervical spine or related areas, taking cues for further examination.

Observation of the patient's attitudes and feelings. The age, gender and ethnicity of patients and their cultural, occupational and social backgrounds will all affect their attitudes and feelings towards themselves, their condition and the clinician. The clinician needs to be aware of and sensitive to these attitudes, and to empathize and communicate appropriately so as to develop a rapport with the patient and thereby enhance the patient's compliance with the treatment.

Joint tests

Joint tests include integrity tests and active and passive physiological movements of the upper cervical spine and other relevant joints. Passive accessory movements complete the joint tests and are described towards the end of the physical examination.

Joint integrity tests (Pettman 1994)

These tests are applicable for patients who have suffered trauma to the spine, such as a whiplash, and who are suspected to have cervical spine instability. The tests described below are considered positive if the patient experiences one or more of the following symptoms: a loss of balance in relation to head movement, unilateral pain along the length of the tongue, facial lip paraesthesia, bilateral or quadrilateral limb paraesthesia, or nystagmus. The patient may require further diagnostic investigations of the upper cervical spine if the clinician finds instability during the tests below.

Distraction tests. With the head and neck in neutral position, the clinician gently distracts the head. If this is symptom-free then the test is repeated with the head flexed on the neck. Reproduction of symptoms suggests upper cervical ligamentous instability, particularly implicating the tectorial membrane (Pettman 1994).

Sagittal stress tests. The forces applied to test the stability of the spine are directed in the sagittal plane and are therefore known as sagittal stress tests. They include anterior and posterior stability tests for the atlanto-occipital joint and two anterior stability tests for the atlanto-axial joint.

Posterior stability test of the atlanto-occipital joint. With the patient supine, the clinician applies an anterior force bilaterally to the atlas and axis on the occiput (Fig. 5.1).

Anterior stability of the atlanto-occipital joint. With the patient supine, the clinician applies a posterior force bilaterally to the anterolateral aspect of the transverse processes of the atlas and axis on the occiput (Fig. 5.2).

Sharp-Perser test. With the patient sitting and the head and neck flexed, the clinician fixes the

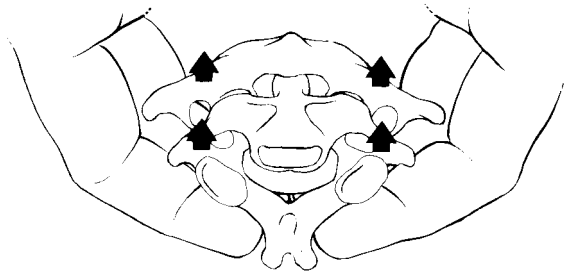

Figure 5.1 Posterior stability test of the atlanto-occipital joint. (From Pettman 1994, with permission.)

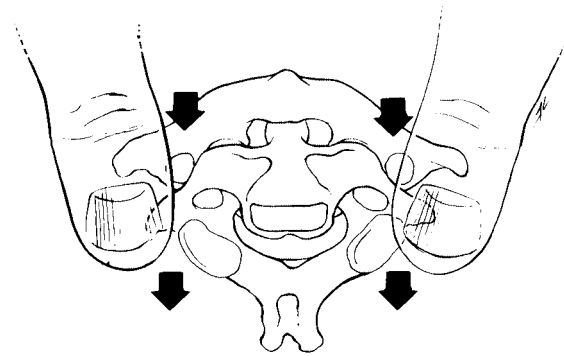


Figure 5.2 Anterior stability of the atlanto-occipital joint. (From Pettman 1994, with permission)

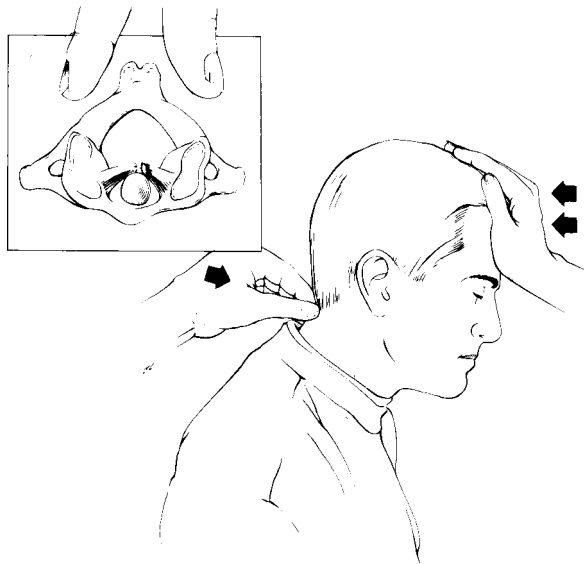


Figure 5.3 Sharp–Perser test of the atlanto-axial joint. (From Pettman 1994, with permission.)

spinous process of C2 and gently pushes the head posteriorly through the forehead to translate the occiput and atlas posteriorly. The test is considered positive, indicating anterior instability of the atlanto-axial joint, if the patient's symptoms are provoked on head and neck flexion and relieved by the posterior pressure on the forehead (Fig. 5.3).

Anterior translation stress of the atlas on the axis. With the patient supine, the clinician fixes C2 (using thumb pressure over the anterior aspect of the transverse processes) and then lifts the head and atlas vertically (Fig. 5.4).

Coronal stress tests. The force applied to test the stability of the spine is directed in the coronal plane and is therefore known as a coronal stress test.

Lateral stability stress test for the atlanto-axial joint. With the patient supine, the clinician supports the occiput and the left side of the arch of the atlas, for example, with the other hand resting over the right side of the arch of the axis. A lateral shear of the atlas and occiput on the axis to the right is attempted. The test is then repeated to the other side. Excessive movement or reproduction of the patient's symptoms suggests lateral instability of this joint (Fig. 5.5).

Alar ligament stress tests. Two stress tests apply a lateral flexion and a rotation stress on the

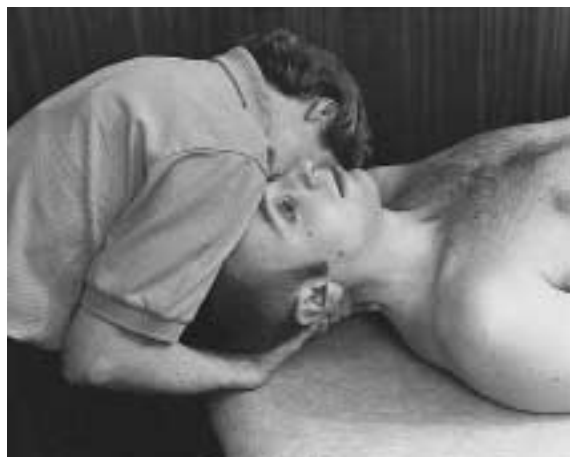

Figure 5.4 Anterior stress test of the atlas on the axis. The left hand grips around the anterior edge of the transverse processes of the axis while the right hand lifts the occiput upwards.

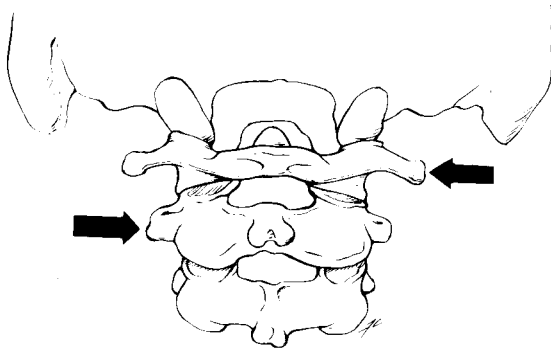


Figure 5.5 Lateral stability stress test for the atlanto-axial joint. (From Pettman 1994, with permission.)

alar ligament (which attaches to the odontoid peg and foramen magnum). The alar ligaments limit contralateral lateral flexion and rotation movement of the occiput on the cervical spine.

Lateral flexion stress test for the alar ligaments. With the patient supine, the clinician fixes C2

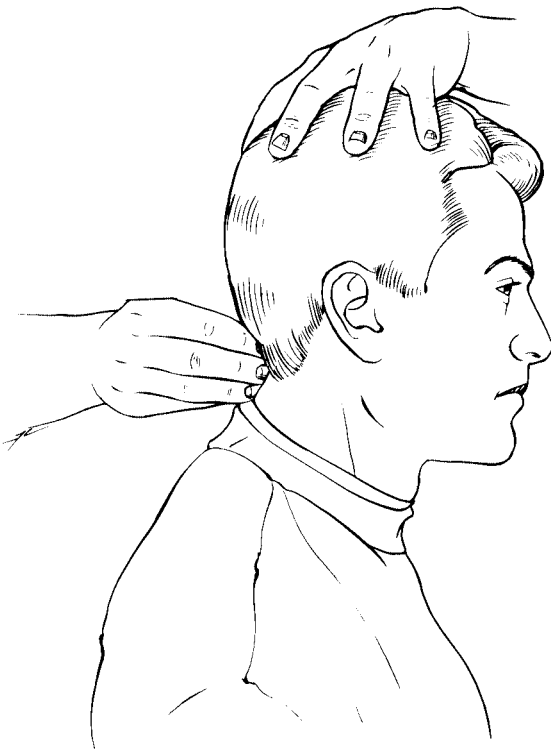

Figure 5.6 Rotational stress test for the alar ligament. (From Pettman 1994, with permission.)

along the neural arch and attempts to flex the craniovertebral joint laterally. No movement of the head is possible if the contralateral alar ligament is intact. The test is repeated with the upper cervical spine in flexion, neutral and extension. If motion is available in all three positions, the test is considered positive, suggesting an alar tear or arthrotic instability at the C0–C1 joint.

Rotational stress test for the alar ligament. This test is carried out if the previous lateral flexion stress test is positive, to determine whether the instability is due to laxity of the alar ligament or due to instability at the C0–C1 joint. In sitting, the clinician fixes C2 by gripping the lamina and then rotates the head. More than 20–30° of rotation indicates a damaged contralateral alar ligament (Fig. 5.6). When the excessive rotational motion is in the same direction as the excessive lateral flexion (from the test above), this suggests damage to the alar ligament; when the excessive motions are in opposite directions, this suggests arthrotic instability (Pettman 1994).

Active and passive physiological joint movement

For both active and passive physiological joint movement, the clinician should note the following:

- The quality of movement (includes clicking or joint noises through the range)
- The range of movement
- The behaviour of pain through the range of movement
- The resistance through the range of movement and at the end of the range of movement
- Any provocation of muscle spasm.

A movement diagram can be used to depict this information.

Active physiological joint movement with over-pressure. The active movements with over-pressure listed below and shown in Figure 5.7 for the upper cervical spine (and in Chapter 6 for the cervical spine) are tested with the patient in sitting.

The clinician establishes the patient's symptom(s) at rest and prior to each movement and corrects any movement deviation to determine its relevance to the patient's symptoms.



Figure 5.7 Overpressures to the upper cervical spine.

A Flexion. The left hand cups around the anterior aspect of the mandible while the right hand grips over the occiput. Both hands then apply a force to cause the head to rotate forwards on the upper cervical spine.

B Extension. The right hand holds underneath the mandible while the left hand and forearm lie over the head. The head and neck are displaced forwards and then both hands apply a force to cause the head to rotate backwards on the upper cervical spine.

C Lateral flexion. The hands grasp around the head at the level of the ears and apply a force to tilt the head laterally on the upper cervical spine.

D Left upper cervical quadrant. The hand position is the same as for upper cervical extension. The head is moved into upper cervical extension and then moved into left rotation and then left lateral flexion.

For the upper cervical spine, the following should be tested:

- Cervical flexion
- Upper cervical flexion
- Cervical extension
- Upper cervical extension
- Left lateral flexion
- Right lateral flexion
- Left rotation
- Right rotation
- Compression
- Distraction

- Left upper cervical quadrant
- Right upper cervical quadrant.

Modifications to the examination of active physiological movements. For further information about the active range of movement the following can be carried out:

- The movement can be repeated several times
- The speed of the movement can be altered
- Movements can be combined (Edwards 1994, 1999). Any number of positions could be used; those described by Edwards are:

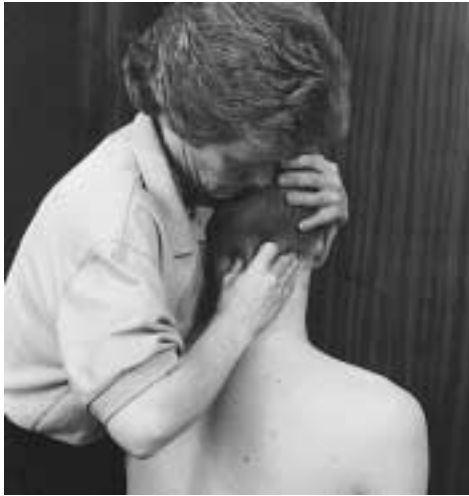

Figure 5.8 Combined movements to the upper cervical spine. The head is supported by the clinician's left hand and forearm and the right hand palpates the upper cervical spine. The left hand then rotates the patient's head and adds flexion while the right hand feels the movement.

- Upper cervical flexion then rotation
- Upper cervical extension then rotation
- Rotation then flexion (shown in Fig. 5.8)
- Rotation then extension
- Compression or distraction in combination with physiological movements
- Movements can be sustained
- The injuring movement, i.e. the movement that occurred at the time of the injury, can be tested
- Differentiation tests.

Numerous differentiation tests (Maitland 1986) can be performed; the choice depends on the patient's signs and symptoms. For example, when cervical flexion reproduces the patient's headache in sitting, the addition of slump sitting (Fig. 3.32) or knee extension may help to differentiate the structures at fault. Slump sitting or knee extension will increase symptoms from abnormal neurodynamics, but will produce no change if the headaches are caused by the joints or soft tissues of the cervical spine.

Capsular pattern. No capsular pattern has been described for the upper cervical spine.

Passive physiological joint movement. This can take the form of passive physiological intervertebral movements (PPIVMs), which examine the

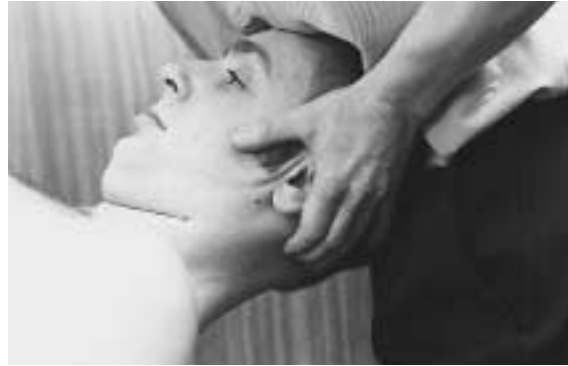

Figure 5.9 Upper cervical flexion PPIVM. The patient lies supine with the head over the end of the couch and supported on the clinician's stomach. The hands are placed so that the index and middle finger lie directly underneath the occiput and between the transverse process of C1 and the mastoid process. The head is then moved into upper cervical flexion and the palpating fingers feel the range of movement.

movement at each segmental level of the spine. PPIVMs can be a useful adjunct to passive accessory intervertebral movements (PAIVMs) to identify segmental hypomobility and hypermobility. It can be performed with the patient supine or sitting. The clinician palpates between adjacent spinous processes or articular pillars to feel the range of intervertebral movement during the following physiological movements: upper cervical flexion and extension, lateral flexion and rotation. Figure 5.9 demonstrates upper cervical flexion PPIVM.

Other joints

Other joints apart from the cervical spine need to be examined to prove or disprove their relevance to the patient's condition. The joints most likely to be a source of symptoms are the temporomandibular joint, lower cervical spine and thoracic spine. These joints can be tested fully (see relevant chapter) or, if they are not suspected to be a source of symptoms, the relevant clearing tests can be used (Table 5.1).

Muscle tests

Muscle tests include examining muscle strength, control, length and isometric contraction.

Table 5.1 Clearing tests

Joint	Physiological movement	Accessory movement
Cervical spine	Quadrants	Palpation
Thoracic spine	Rotation and quadrants	Palpation
Temporomandibular joint	Open/close jaw, side to side movement, protraction/retraction	Posteroanterior and medial glide

Muscle strength

The clinician should test the cervical flexors, extensors, lateral flexors and rotators. For details of these general tests, the reader is directed to Daniels & Worthingham (1986), Cole et al (1988) or Kendall et al (1993).

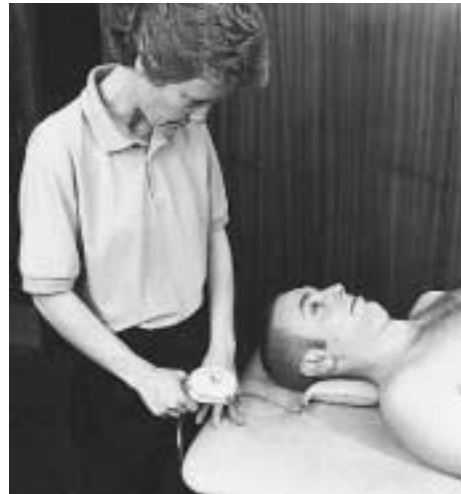Greater detail may be required to test the strength of individual muscles, in particular those muscles prone to become weak (Janda 1994), which include serratus anterior, middle and lower fibres of trapezius and the deep neck flexors. Testing the strength of these muscles is described in Chapter 3.

Muscle control

The relative strength of muscles is considered to be more important than the overall strength of a muscle group (Janda 1994). Relative strength is assessed indirectly by observing posture as already mentioned, by the quality of active movement, noting any changes in muscle recruitment patterns, and by palpating muscle activity in various positions.

In the neck, the deep neck flexors together with the muscles of the shoulder girdle are the important muscles that support and control the joints of the neck. Individual testing of the following muscles may be necessary: longus colli, longus capitis, upper, middle and lower fibres of trapezius and serratus anterior. These muscles stabilize the neck by supporting the weight of the head against gravity and allowing efficient functional activity of the upper limbs.

Weak deep neck flexors have been found to be associated with cervicogenic headaches (Watson

**Figure 5.10** Testing the strength of the deep neck flexors.

1994). These muscles are tested by the clinician observing the pattern of movement which occurs when the patient flexes the head from a supine position. When the deep neck flexors are weak, the sternocleidomastoid initiates the movement, causing the jaw to lead the movement and the upper cervical spine to hyperextend. After about 10° of head elevation, the cervical spine then curls up into flexion.

A pressure biofeedback unit (PBU; Chattanooga, Australia) can be used to measure the function of the deep neck flexors more objectively (Jull 1994). The patient lies supine with a towel under the head to position the cervical spine in neutral, ensuring that the head is parallel to the ceiling. The PBU is placed under the cervical spine and inflated to fill the suboccipital space, to around 20 mmHg. The patient is then asked to carry out a gentle nod of the head, which should increase the pressure in the normal by 6–10 mmHg (Fig. 5.10). Normal function of the deep neck flexors is considered to be the ability to hold this contraction for 10 seconds and repeat the contraction 10 times (Jull, personal communication, 1999). The emphasis is on low load endurance and the patient should be able to sustain a pressure not exceeding 30 mmHg. Inability to hold an even pressure may indicate poor endurance of the deep neck flexors. Nodding of

the head should occur without any activity in the superficial muscles of the neck. The clinician may be able to palpate sternocleidomastoid to feel for unwanted muscle activity.

Muscle length

The clinician tests the length of individual muscles, in particular those muscles that are prone to become short (Janda 1994), i.e. the levator scapula, upper trapezius, sternocleidomastoid, pectoralis major and minor, scalenes and the deep occipital muscles. Testing the length of these muscles is described in Chapter 3.

Isometric muscle testing

Test the cervical spine flexors, extensors, lateral flexors and rotators in resting position and, if indicated, in different parts of the physiological range. This is usually carried out with the patient in sitting but may be done in supine. In addition the clinician observes the quality of the muscle contraction to hold this position (this can be done with the patient's eyes shut). The patient may, for example, be unable to prevent the joint from moving or may hold with excessive muscle activity; either of these circumstances would suggest a neuromuscular dysfunction.

Neurological tests

Neurological examination involves examining the integrity of the nervous system, the mobility of the nervous system and specific diagnostic tests.

Integrity of the nervous system

Generally, if symptoms are localized to the upper cervical spine and head, neurological examination can be limited to C1–4 nerve roots.

Dermatomes/peripheral nerves. Light touch and pain sensation of the face, head and neck are tested using cotton wool and pinprick respectively, as described in Chapter 3. A knowledge of the cutaneous distribution of nerve roots (dermatomes) and peripheral nerves enables the clinician to distinguish the sensory loss due to a root

lesion from that due to a peripheral nerve lesion. The cutaneous nerve distribution and dermatome areas are shown in Figure 3.18.

Myotomes/peripheral nerves. The following myotomes are tested and are shown in Figure 3.26.

- C1–2 – upper cervical flexion
- C2 and 5th cranial – upper cervical extension
- C3 and 5th cranial – cervical lateral flexion
- C4 – shoulder girdle elevation.

A working knowledge of the muscular distribution of nerve roots (myotomes) and peripheral nerves enables the clinician to distinguish the motor loss due to a root lesion from that due to a peripheral nerve lesion. The facial nerve (7th cranial) supplies the muscles of facial expression, while the mandibular nerve (5th cranial) supplies the muscles of mastication.

Reflex testing. There are no deep tendon reflexes for C1–4 nerve roots.

Mobility of the nervous system

The following neurodynamic tests may be carried out in order to ascertain the degree to which neural tissue is responsible for the production of the patient's symptom(s):

- Passive neck flexion (PNF)
- Upper limb tension tests (ULTT)
- Straight leg raise (SLR)
- Slump.

These tests are described in detail in Chapter 3.

Other neural diagnostic tests

Plantar response to test for an upper motor neurone lesion (Walton 1989). Pressure applied from the heel along the lateral border of the plantar aspect of the foot produces flexion of the toes in the normal. Extension of the big toe with downward fanning of the other toes occurs with an upper motor neurone lesion.

Special tests

In the case of the upper cervical spine, the special tests are *vascular tests*.

Table 5.2 Vertebral artery test (Grant 1994)

Patient does not complain of symptoms related to VBI and manipulation is the choice of treatment	Patient complains of symptoms related to VBI
<p>In sitting or lying:</p> <ul style="list-style-type: none"> • Sustained extension • Sustained L rotation • Sustained R rotation • Sustained L rotation/extension • Sustained R rotation/extension • Pre-manipulation position 	<p>In sitting:</p> <ul style="list-style-type: none"> • Sustained extension • Sustained L rotation • Sustained R rotation • Sustained L rotation/extension • Sustained R rotation/extension • Rapid movements • Sustained movements (more than 10 s) • Any other movement

Vertebral artery test (Grant 1994). There are two sets of tests, one for patients who do not complain of any dizziness or other symptoms related to vertebrobasilar insufficiency (VBI) and for whom manipulation is the choice of treatment, and another for patients who do have symptoms of VBI. These tests are outlined in Table 5.2.

For all tests, the movements are active and each position is maintained by the clinician giving gentle overpressure for a minimum of 10 seconds. The movement is then released for 10 seconds before the next movement is carried out. If dizziness, nausea or any other symptom associated with vertebrobasilar insufficiency (disturbance in vision, diplopia, nausea, ataxia, 'drop attacks', impairment of trigeminal sensation, sympathoplegia, dysarthria, hemianaesthesia and hemiplegia) (Bogduk 1994) is provoked during any part of the test, it is considered positive and testing should be stopped immediately. If the test is positive, this contraindicates manipulation of the cervical spine.

Differentiation between dizziness produced from the vestibular apparatus of the inner ear and that from the neck movement (due to cervical vertigo or compromised vertebral artery) may be required. In standing, the clinician maintains head position while the patient moves the trunk to produce cervical rotation. This position is held for at least 10 seconds. The patient then repeats this movement in the opposite direction. The test is considered positive and stopped immediately if dizziness, nausea or any other symptom associated with vertebrobasilar insufficiency is provoked, suggesting that the patient's

symptoms are not caused by a disturbance of the vestibular system. A positive vertebral artery test contraindicates certain treatment techniques to the cervical spine (Table 2.3).

Palpation of pulses. If the circulation is suspected of being compromised, the clinician palpates the pulses of the carotid, facial and temporal arteries.

Functional ability

Some functional ability has already been tested by the general observation of the patient during the subjective and physical examinations, e.g. the postures adopted during the subjective examination and the ease or difficulty of undressing prior to the examination. Any further functional testing can be carried out at this point in the examination and may include sitting postures or certain movements of the upper limb, etc. Clues for appropriate tests can be obtained from the subjective examination findings, particularly aggravating factors.

Palpation

The cervical spine is palpated, as well as the head, face, thoracic spine and upper limbs, as appropriate. It is useful to record palpation findings on a body chart (see Fig. 2.4) and/or palpation chart (see Fig. 3.37).

The clinician should note the following:

- The temperature of the area
- Localized increased skin moisture
- The presence of oedema or effusion

- Mobility and feel of superficial tissues, e.g. ganglions, nodules, thickening of deep suboccipital tissues
- The presence or elicitation of any muscle spasm
- Tenderness of bone, ligaments, muscle, tendon, tendon sheath and nerve. Check for tenderness in suboccipital region. Test for the relevant trigger points shown in Figure 3.38
- Increased or decreased prominence of bones
- Pain provoked or reduced on palpation.

Passive accessory intervertebral movements (PAIVMs)

It is useful to use the palpation chart and movement diagrams (or joint pictures) to record findings. These are explained in detail in Chapter 3.

The clinician should note the following:

- The quality of movement
- The range of movement

- The resistance through the range and at the end of the range of movement
- The behaviour of pain through the range
- Any provocation of muscle spasm.

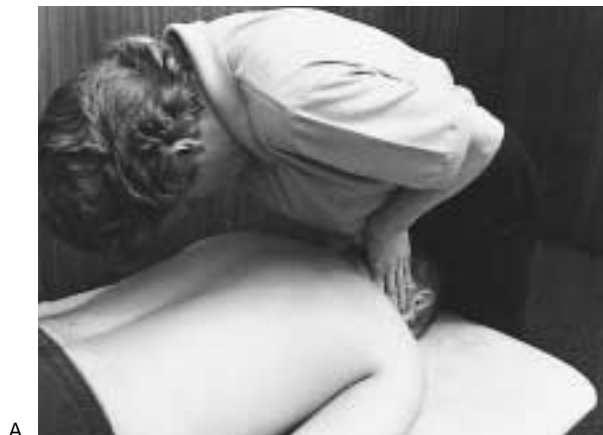Upper cervical spine (C1–C4) accessory movements

The upper cervical spine accessory movements (Maitland 1991) are as follows:

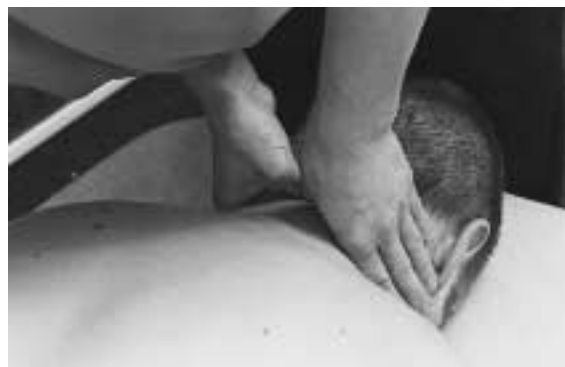↓	central posteroanterior
↖↗	unilateral posteroanterior
→	med transverse for C1
→ ←	transverse for C2–4
↙↘	unilateral anteroposterior.

The accessory movements for C1 are shown in Figure 5.11 (for the other levels see Fig. 6.4).

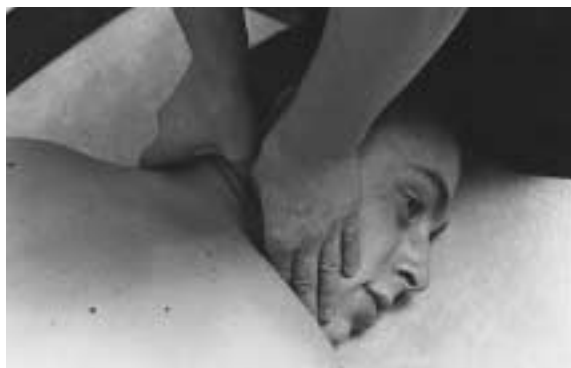For further information when examining the accessory movements, the clinician alters the:



A



B



C

Figure 5.11 Accessory movements to C1.

A Central posteroanterior. Thumb pressure is applied over the posterior arch of C1 and directed upwards and forwards towards the patient's eyes.

B Unilateral posteroanterior. Thumb pressure is applied laterally over the posterior arch of C1.

C Transverse pressure on the right. The head is rotated to the right and thumb pressure is applied to the transverse process of C1.

- Speed of force application
- Direction of the applied force
- Point of application of the applied force
- Position of the joint – for example, accessory movement can be carried out with the cervical spine placed in a variety of positions (Edwards 1994, 1999).

Atlanto-occipital joint. Apply anteroposterior (AP) and/or posteroanterior (PA) unilateral pressures on C1 with the spine positioned in flexion and rotation or extension and rotation, so as to increase and/or decrease the compressive or stretch effect at the atlanto-occipital joint:

- A PA on the right of C1 with the spine in flexion and right rotation will increase the stretch at the right C0–C1 joint (Fig. 5.12); an AP on the right of C1 will decrease the stretch
- An AP on the left of C1 with the spine in extension and right rotation will increase the stretch on the left C0–C1 joint; a PA on the left of C1 will decrease the stretch.

Atlanto-axial joint. Apply AP and/or PA unilateral vertebral pressures on C1 and/or C2 with the spine positioned in rotation and flexion or rotation and extension so as to increase and/or decrease the compressive or stretch effect at the atlanto-axial joint:

- A PA on the left of C1 with the head in right rotation and flexion will increase the stretch at

the left C1–C2 joint; a PA on C2 will decrease this stretch

- A PA on the left of C2 with the head in left rotation and extension will increase the rotation at the C1–C2 joint; a PA on C1 will decrease the rotation
- An AP on left of C2 with the head in right rotation and flexion will increase the rotation at the C1–C2 joint; an AP on C1 will decrease the rotation
- An AP on the left of C1 with the head in left rotation and extension will increase the rotation at the C1–C2 joint (Fig. 5.13); an AP on C2 will decrease the rotation.

Following accessory movements the clinician reassesses all the asterisks (movements or tests that have been found to reproduce the patient's symptoms) in order to establish the effect of the accessory movements on the patient's signs and symptoms. This helps to prove/disprove the structure(s) at fault.

Other joints as applicable

Accessory movements can then be tested for other joints suspected to be a source of the symptoms, and by reassessing the asterisks the clinician is then able to prove/disprove the structure(s) at fault. Joints likely to be examined are the temporomandibular joint, lower cervical spine and the thoracic spine.

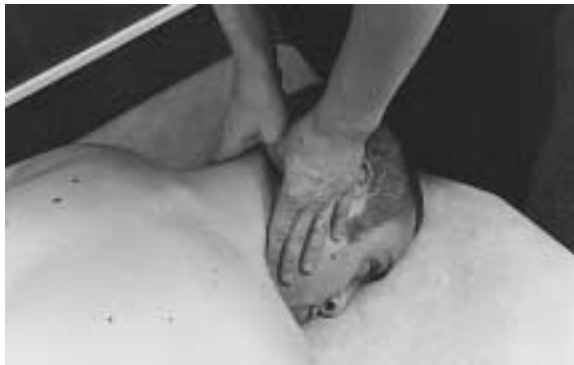

Figure 5.12 Palpation for the C0–C1 joint using combined movements. Thumb pressure over the right of the posterior arch of the atlas is applied with the patient's head in flexion and right rotation.

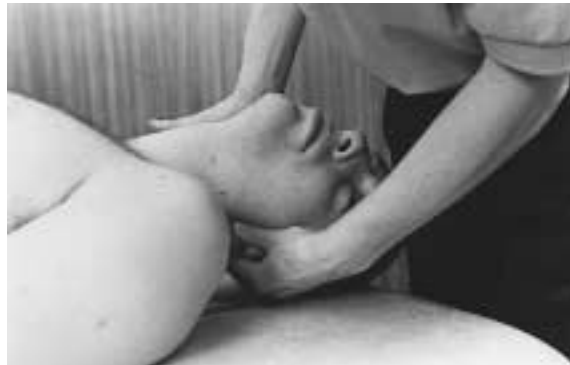

Figure 5.13 Palpation for the C0–C1 joint using combined movements. Thumb pressure over the anterior aspect of the atlas on the left is applied with the head in left rotation and extension.

Sustained natural apophyseal glides (SNAGs)

The painful cervical spine movements are examined in sitting. Pressure to each spinous process and/or transverse process of the cervical vertebrae is applied by the clinician as the patient moves slowly towards the pain (Mulligan 1995). Figure 5.14 demonstrates a SNAG to the spinous process of C4 as the subject moves into cervical

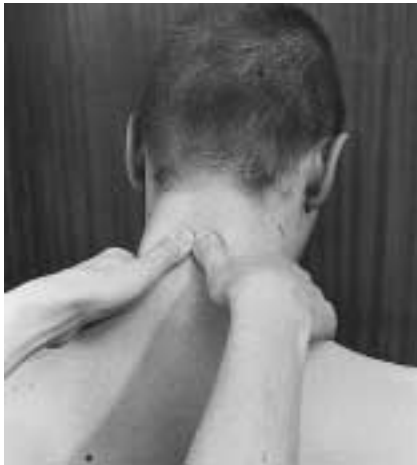

Figure 5.14 A SNAG. A posteroanterior pressure is applied to C4 as the subject moves into cervical flexion.

flexion. The symptomatic level will be one in which the pressure reduces the pain. For further information, refer to Chapter 3.

For patients complaining of headaches, Mulligan (1995) describes four examination techniques.

Headache SNAGs. The clinician applies a posteroanterior pressure to C2 on a stabilized occiput with the patient in sitting (Fig. 5.15). The pressure is sustained for at least 10 seconds while the patient remains still; there is no active movement. The test is considered positive if the headache is relieved, which would indicate a mechanical joint problem.

Reverse headache SNAGs. The clinician moves the occiput anteriorly on the stabilized C2 with the patient in sitting (Fig. 5.16). The movement is sustained for at least 10 seconds while the patient remains still; there is no active movement. Again the test is considered positive if the headache is relieved, which would indicate a mechanical joint problem.

Upper cervical traction. The clinician maintains the patient's cervical lordosis by placing a forearm under the cervical spine with the patient supine (Fig. 5.17). Pronation of the forearm and a gentle pull on the chin produces cervical traction.

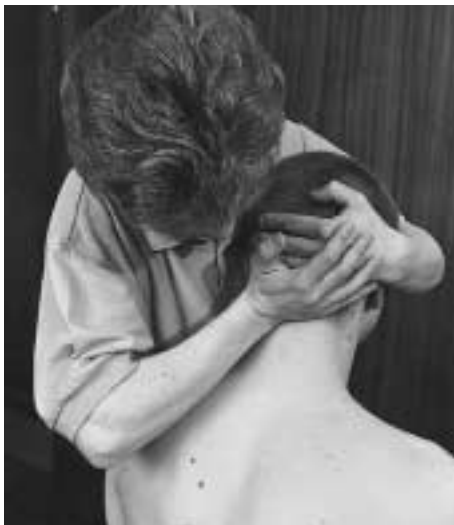

Figure 5.15 Headache SNAG. A posteroanterior pressure is applied to C2 using the heel of the right hand. The left hand supports the head.

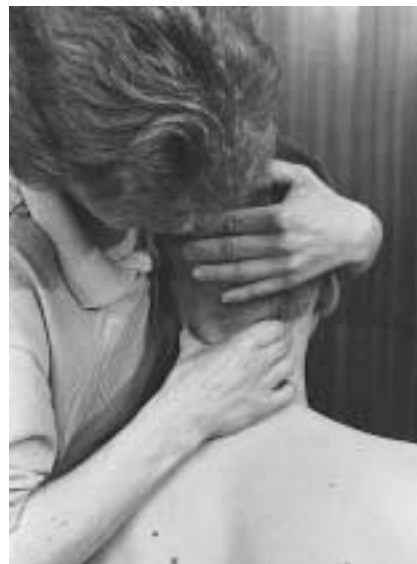

Figure 5.16 Reverse headache SNAG. The right hand palpates the transverse processes of C2. The left hand supports and moves the head anteriorly on the stabilized C2.

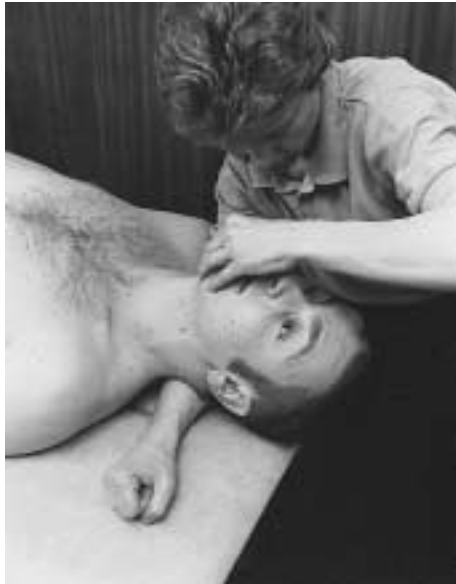

Figure 5.17 Cervical traction. The patient lies supine and the clinician's forearm is placed under the patient's cervical spine. The left hand grips the mandible and applies a gentle traction force.

The position is held for at least 10 seconds; relief of symptoms indicates a positive test, which would indicate a mechanical joint problem.

SNAGs for restricted cervical rotation at C1–2. The painful cervical spine movements are exam-

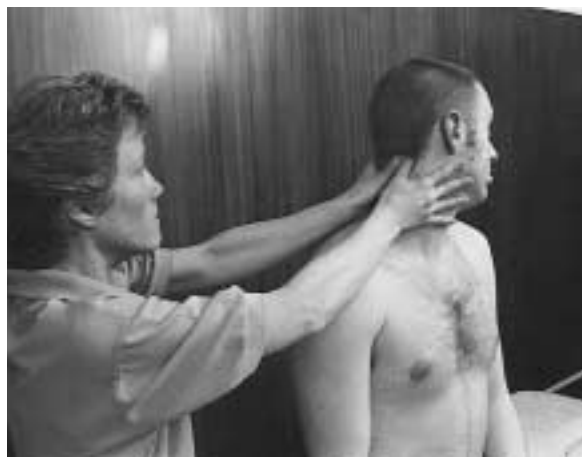

Figure 5.18 SNAGs for restricted cervical rotation at C1–2. A posteroanterior pressure is applied to the right articular pillar of C1 as the patient moves slowly into left rotation.

ined in sitting. Pressure to the left or right side of the posterior arch of C1 is applied by the clinician as the patient slowly rotates to the right or left side towards the pain (Fig. 5.18). Pain-free movement indicates a positive test and would indicate a mechanical joint problem.

COMPLETION OF THE EXAMINATION

Having carried out the above tests, the examination of the upper cervical spine is now complete. The subjective and physical examinations produce a large amount of information, which needs to be recorded accurately and quickly. An outline examination chart may be useful for some clinicians and one is suggested in Figure 5.19. It is important, however, that the clinician does not examine in a rigid manner, simply following the suggested sequence outlined in the chart. Each patient presents differently and this should be reflected in the examination process. It is vital at this stage to highlight with an asterisk (*) important findings from the examination. These findings must be reassessed at, and within, subsequent treatment sessions to evaluate the effects of treatment on the patient's condition.

On completion of the physical examination, the clinician should:

- Warn the patient of possible exacerbation up to 24–48 hours following the examination.
- Request the patient to report details on the behaviour of the symptoms following examination at the next attendance.
- Explain the findings of the physical examination and how these findings relate to the subjective assessment. An attempt should be made to clear up any misconceptions patients may have regarding their illness or injury.
- Evaluate the findings, formulate a clinical diagnosis and write up a problem list. Clinicians may find the management planning forms shown in Figures 3.51 and 3.52 helpful in guiding them through what is often a complex clinical reasoning process.
- Determine the objectives of treatment.
- Devise an initial treatment plan.

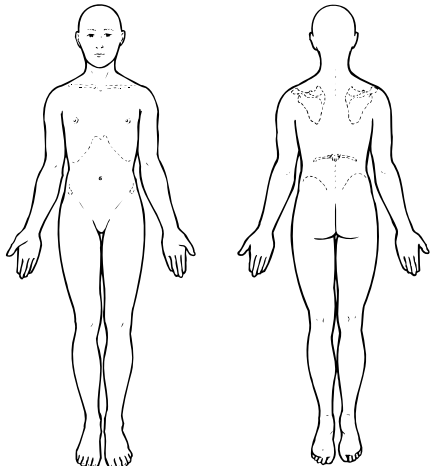
<p>Subjective examination</p> <p>Body chart</p> <div style="text-align: center;">  </div> <p>Relationship of symptoms</p>	Name Age Date
	24 hour behaviour
Aggravating factors	Function
Severe Irritable Easing factors	Improving Static Worsening
No pain Pain as bad as it could possibly be	Special questions General health Weight loss RA Drugs Steroids Anticoagulants X-ray Cord symptoms Dizziness
	HPC
	PMH
	SH & FH
<i>Intensity of pain</i>	

Figure 5.19 Upper cervical spine examination chart.

<p>Physical examination</p> <p><i>Observation</i></p>	<p>Muscle control (head flexion)</p>
<p><i>Joint tests</i> Joint integrity tests (distraction, anterior and posterior stability C0–C1, Sharp-Perser for C1–C2, lateral stability C1–C2 and alar stress tests)</p>	<p>Muscle length</p> <p>Isometric muscle tests</p>
<p>Active and passive joint movement Cervical flexion Upper cervical flexion Cervical extension Upper cervical extension L lat flexion R lat flexion L rotation R rotation Compression Distraction L upper cervical quadrant R upper cervical quadrant</p> <p>Repeated movements</p> <p>Combined movements</p> <p>PPIVMs</p> <p>Other joints</p>	<p><i>Neurological tests</i> Integrity of the nervous system</p> <p>Mobility of the nervous system</p> <p>Diagnostic tests (plantar response)</p>
	<p><i>Special tests</i> (vertebral artery and pulses)</p>
	<p><i>Function</i></p>
	<p><i>Palpation</i></p>
	<p><i>Accessory movements</i></p>
<p><i>Muscle tests</i> Muscle strength</p>	<p><i>Other joints</i></p>
	<p>SNAGS</p>

Figure 5.19 (cont'd)

REFERENCES

- Barker S, Kesson M, Ashmore J, Turner G, Conway J, Stevens D (2000) Guidance for pre-manipulative testing of the cervical spine. *Manual Therapy* 5(1): 37–40
- Bogduk N 1994 Cervical causes of headache and dizziness. In: Boyling J D, Palastanga N (eds) *Grieve's modern manual therapy*, 2nd edn. Churchill Livingstone, Edinburgh, ch 22, p 317
- Clinical Standards Advisory Report 1994 Report of a CSAG committee on back pain. HMSO, London
- Cole J H, Furness A L, Twomey L T 1988 Muscles in action, an approach to manual muscle testing. Churchill Livingstone, Edinburgh
- Dahlberg C, Lanig I S, Kenna M, Long S 1997 Diagnosis and treatment of esophageal perforations in cervical spinal cord injury. *Topics in Spinal Cord Injury Rehabilitation* 2(3): 41–48
- Daniels L, Worthingham C 1986 Muscle testing, techniques of manual examination, 5th edn. W B Saunders, Philadelphia, PA
- Edeling J 1988 *Manual therapy for chronic headache*. Butterworths, London
- Edwards B C 1994 Examination of the high cervical spine (occiput–C2) using combined movements. In: Boyling J D, Palastanga N (eds) *Grieve's modern manual therapy*, 2nd edn. Churchill Livingstone, Edinburgh, ch 41, p 555
- Edwards B C 1999 *Manual of combined movements: their use in the examination and treatment of mechanical vertebral column disorders*, 2nd edn. Butterworth-Heinemann, Oxford
- Grant R 1994 Vertebral artery concerns: pre-manipulative testing of the cervical spine. In: Grant R (ed) *Physical therapy of the cervical and thoracic spine*, 2nd edn. Churchill Livingstone, New York, ch 8, p 145
- Grieve G P 1994 Counterfeit clinical presentations. *Manipulative Physiotherapist* 26: 17–19
- Headache Classification Committee of the International Headache Society 1988 Classification and diagnostic criteria for headache disorders, cranial neuralgias and facial pain. *Cephalalgia* 8(7): 9–96
- Jackson R 1966 *The cervical syndrome*, 3rd edn. Charles C Thomas, Springfield, IL
- Janda V 1994 Muscles and motor control in cervicogenic disorders: assessment and management. In: Grant R (ed) *Physical therapy of the cervical and thoracic spine*, 2nd edn. Churchill Livingstone, New York, ch 10, p 195
- Jull G A 1994 Headaches of cervical origin. In: Grant R (ed) *Physical therapy of the cervical and thoracic spine*, 2nd edn. Churchill Livingstone, New York, ch 13, p 261
- Kendall F P, McCreary E K, Provance P G 1993 *Muscles testing and function*, 4th edn. Williams & Wilkins, Baltimore, MD
- Maitland G D 1986 *Vertebral manipulation*, 5th edn. Butterworths, London
- Maitland G D 1991 *Peripheral manipulation*, 3rd edn. Butterworths, London
- Mulligan B R 1995 *Manual therapy 'nags', 'snags', 'MWMs' etc.*, 3rd edn. Plant View Services, New Zealand
- Pettman E 1994 Stress tests of the craniovertebral joints. In: Boyling J D, Palastanga N (eds) *Grieve's modern manual therapy*, 2nd edn. Churchill Livingstone, Edinburgh, ch 38, p 529
- Walton J H 1989 *Essentials of neurology*, 6th edn. Churchill Livingstone, Edinburgh
- Watson D H 1994 Cervical headache: an investigation of natural head posture and upper cervical flexor muscle performance. In: Boyling J D, Palastanga N (eds) *Grieve's modern manual therapy*, 2nd edn. Churchill Livingstone, Edinburgh, ch 24, p 349

